

Control of Gastrointestinal Bleeding

In the Endoscopy Department Bleeding in the Gastrointestinal tract is controlled one or more of several methods. The preferred methods include injection of a medication called epinephrine at the bleeding site, placing direct pressure on the bleeding site by means of attaching a metal clip to the bleeding site, and coagulation of the bleeding site by passing a cautery (burning) probe through the scope and heating the tissue at the bleeding site to coagulation temperature.

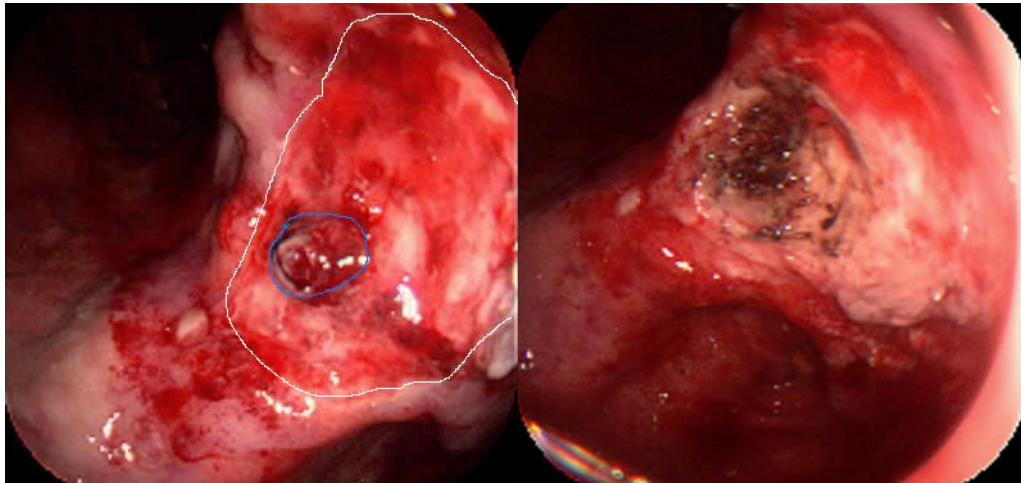


Figure 1

Figure2

Figure 1 is a stomach ulcer that has eroded the tissue down to a blood vessel. It has been bleeding from the vessel (circled in blue) you see protruding from the base of the ulcer. The margin of this ulcer is marked with a white line.

Figure 2 is the same ulcer from a slightly different angle after it has been cauterized. (The tissue is coagulated.)

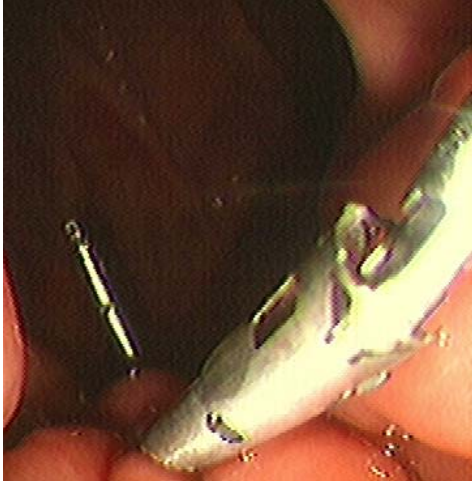

Figure 3

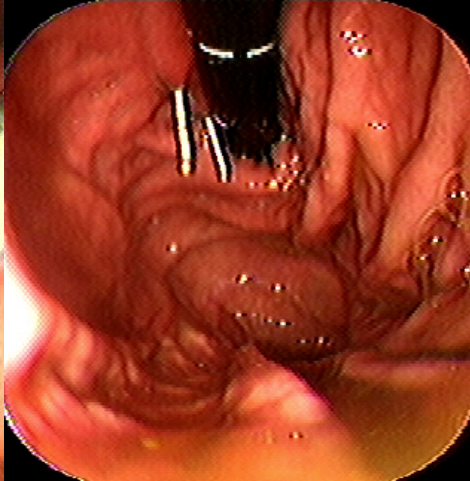


Figure 4

These two pictures show clips in place on a bleeding site.

Figure 3 was taken immediately after placement of the clips and **Figure 4** was taken the next day to verify continued control of bleeding.